

# FEATURES OF REARFOOT INJURIES IN PATIENTS WITH MULTISYSTEM TRAUMA

*V.B. Bondarev, V.O. Kalensky, P.A. Ivanov*

N.V. Sklifosovsky Research Institute for Emergency Medicine, Moscow, Russian Federation

<b>BACKGROUND</b>	Rearfoot injuries occur 2.5 times more often in a multisystem trauma than in patients with an isolated injury. The foot trauma is often misdiagnosed at the stage of intensive care treatment. Up to 22% of victims with foot injuries become disabled.
<b>AIM OF THE STUDY</b>	The aim of the study is to determine distinctive characteristics of rearfoot injuries in patients with multisystem trauma.
<b>MATERIAL AND METHODS</b>	We performed a retrospective study of 89 cases of rearfoot injuries in patients admitted to the N.V. Sklifosovsky Research Institute for Emergency Medicine in 2011–2013.
<b>RESULTS</b>	There were 128 calcaneus and talus fractures. Middle-aged male patients (39±14.5 years) prevailed.
<b>CONCLUSION</b>	We found several peculiarities: the common mechanism of an injury was the fall from a height (64%). Up to 40% of patients with multisystem trauma had injuries of two and more anatomic areas. The multisystem spinal (lower thoracic and lumbar) injury was detected in 29% of patients. In 38% of cases we revealed polysegmental fractures of lower limbs. In patients with polytrauma, multiple foot injuries were diagnosed in 31 cases (35%), most common were bilateral calcaneus fractures. We also diagnosed 60% of Gustilo and Anderson open fractures of III type.
<b>Keywords:</b>	polytrauma, calcaneus fractures, talus fractures.

TBI — traumatic brain injury

RTA — road traffic accident

## BACKGROUND

Damage to the rearfoot, including talus and calcaneal bone in victims with multisystem trauma occur 2.5 times more often than in patients with isolated injuries. This is associated with a typical mechanism of injury such as the fall from a height and road traffic accidents (RTA). In 35–43% of cases, rearfoot fractures occur as a part of polytrauma, accompanied by the rupture or contusion of internal organs and bone fractures at other sites [1]. Fractures are often multiple, bilateral, largely displaced and comminuted. About 20% of such fractures are open [2]. These features have a direct impact on the complexity of surgery, the possibility of rehabilitation and as a result affect the functional outcome.

It should be noted that foot lesions in patients with multisystem foot trauma often remain undiagnosed in the early post-traumatic period. In serious patients with injuries of several areas, foot fractures are hidden with more significant damage. According to the literature, in 8 and 25% of fractures of the foot and ankle joint are diagnosed late in these patients. [3]

Against the background of severe concomitant injury, the diagnosis and treatment of fractures of rearfoot are not always given due attention, as in the treatment of this group of victims the priority is to perform life-saving manipulation and that is why the surgical treatment is delayed [1, 5]. However, after 4–5 weeks, if a surgery was indicated, but had been performed, there could be additional difficulties associated with initiated consolidation of bone fragments. Often, the risk of postoperative complications becomes high by that time because of the large trauma, difficulty of fragments repositioning and increasing surgery duration.

The postoperative period in patients with delayed reposition of fragments is characterized with higher incidence of local inflammatory complications due to severe somatic condition: post-hemorrhagic anemia, secondary immune deficiency, tissue hypoxia of different origin [2].

Traumatic injuries of the foot significantly affect the patient's quality of life and working life. Although these damages are not life threatening, it often seriously affects the patient's physical and social activities, leading to psychological disorders. In some cases, the foot trauma has a greater functional damage than injuries of larger

segments of the skeletal system [6]. In patients with a concomitant injury, the most common cause of complaints in the long term period is consequences of foot and ankle-joint injuries, resulting in claudication and walking disturbances. Up to 22% of victims with foot and ankle injuries subsequently become incapable of working and physically challenged [4, 6].

**Aim of study:** to determine the characteristics of traumatic lesions of the rearfoot in patients with multisystem trauma.

## MATERIAL AND METHODS

We performed a retrospective analysis of 89 patients with foot injuries, admitted to the N.V. Sklifosovsky Research Institute for Emergency Medicine in 2011-2013. We collected data on demographics, mechanism of trauma, combination of injuries, the severity of injuries according to *ISS*, multiplicity of feet damage, the nature of calcaneal fractures, types of calcaneal fractures according to *R. Sanders* and types of talus fractures according to *L.G. Hawkins*.

The average age of victims was  $39.3 \pm 14.1$ . There were 56 people (63%) of young and middle age (below 41 years) (Figure 1).

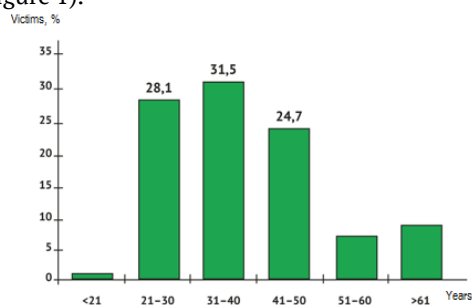


Fig. 1. Distribution of victims by age

Most of the victims were men, 66 patients (74.2%). And 45.8% of female victims were of active childbearing age (21- 30).

The citizens, not officially working prevailed — 52 patients (58.4%). There were 7 homeless people 7 (7.9%).

At the time of the injury, 26 people (29.2%) were under alcoholic or narcotic intoxication.

In 6 patients, concomitant parenteral infections (HIV, hepatitis, syphilis) were reported (6.7%).

To determine the leading damage in patients with the injury of several areas of the body we used the *AIS* scale. *ISS* scale was used to assess the severity of the associated injuries.

The CT was performed in 77 cases (80.2%) of 96 to identify the calcaneus fractures, and findings allowed to distribute injuries according to *R. Sanders* classification (1993).

Classification of *L.G. Hawkins* (1970) modified by *S.T. Canale* and *F.B. Kelly* (1978) was used to assess the nature of fragment displacement in fractures of the neck of talus.

In 11 patients of 89, rearfoot fractures were not diagnosed upon admission due to the severity of accompanying injuries. Functional outcomes in these patients were evaluated according to *Foot Function Index (FFI)*.

## RESULTS

The fall from a height was the mechanism of injury for most patients (57 cases, 64.0%). In 12 cases, it was a suicide. The second most frequent mechanism of injury was a road traffic accident (24 cases, 26.9%).

It should be noted that the scope and nature of trauma was determined by the force of traumatic effects and mechanism of injury.

Thus, in 26 patients (45.6%) of 57 cases of catatrauma, rearfoot injuries were diagnosed in combination with fractures of the lumbar and lower thoracic vertebrae. This combination of lesions occurred both isolated (6 cases, 10.5%) and in combination with damages to other sites: 12 cases (21.1%) of a fractured pelvis, 3 cases (5.3%) of TBI, 6 cases (10.5%) of fractures of lumbar and lower thoracic vertebrae, fractured pelvis and closed chest injury.

There was another situation in case of road traffic accidents. For example, in 19 cases (86%) of injuries inside a vehicle, rearfoot damages were combined with other injuries of the musculoskeletal system. There was no combination of a foot injury with fractures of lumbar and lower thoracic vertebrae. In 14 victims (64%), we diagnosed a chest injury in various combinations. In 5 patients, multiple fractures were combined with closed chest trauma and TBI, in 2 — only with TBI. In 2 patients, multiple skeletal injuries were combined with closed chest trauma, head injury, and damage to the abdominal cavity. The most frequent concomitant damage in the group of 22 patients was a femur fracture (12 cases, 54.5%), fracture of the lower leg bones (9 cases, 40.9%), upper extremity fractures (6 cases, 27.3%), pelvic fractures (5 cases, 22.3%).

The following results (Table 1) were obtained when distributing patients according to the severity of injuries.

Table 1

### Distribution of victims by the severity of damage (*ISS*)

<i>ISS</i> score	Number of patients
------------------	--------------------

	abs.	%
<17	27	37.0
17-25	27	37.0
26-40	16	21.9
> 40	3	4.1
Total	73	100

In patients with rearfoot injuries, multisystem and multiple trauma of moderate severity (<25, *ISS*) and heavy trauma not threatening patient's life (17-25) prevailed. There were 54 (74%) patients with *ISS* <25. It is noteworthy that severe polytrauma (*ISS* >26) was observed in 26% of cases and was typical for patients who had suffered as a result of falling from a height. There were no patients after falling from a height with *ISS* below 18.

The multisystem trauma of the musculoskeletal system in 40 patients (54.8%) prevailed among underlying injuries. The chest trauma occurred in 13 patients as the leading damage (17.8%), spinal cord injury – in 7 (9.6%), head injury – in 5 (6.8%). Severe patients with damage to more than two anatomical regions accounted for 39.7% (29 cases).

In 89 patients admitted in 2011-2013, there were 128 rearfoot injuries, including fractures of the calcaneus 96 (53 left and 43 right), 26 fractures of the talus and 6 subtalar dislocations. Multiple rearfoot lesions were diagnosed in 31 victims (34.8%) (Table 2).

Table 2

#### Distribution of multiple rearfoot injuries

Possible combinations damage	Number of victims	
	abs.	%
Bilateral fracture of the calcaneus	21	67.7
Bilateral fracture of the talus	2	6.5
Ipsilateral fracture of the talus and calcaneus bones	2	6.5
Contralateral fracture of the talus and calcaneus bones	2	6.5
Talus fracture and ipsilateral subtalar dislocation	3	9.7
Talus fracture and contralateral subtalar dislocation	1	3.2
Total:	31	100

The high incidence of bilateral fractures of the calcaneus should be noted. Treatment of these patients is a challenge, as it excludes the possibility of early mobilization, which is extremely important for patients with associated trauma as a whole.

We revealed 42 (54.5%) rearfoot fractures of type II, 22 fractures of type III (28.6%) and 13 fractures of type IV (16.9%) in this classification. It is noteworthy that there were no type I fractures, more typical for an isolated injury.

We identified one rearfoot fracture of type I (3.8%), 4 fractures of type II (15.4%), 10 fractures of type III (38.5%), 3 fractures of type IV (11.5%). Seven of 26 lesions of the talus (26.9) were trochlear fractures. In one case (3.8%), we observed a fracture of the talar head. Thus, fractures of the neck of talus and trochlear fractures with displacement dominated, characterized by a high incidence of avascular necrosis (fractures of the neck of type II-IV and trochlear fractures with displacement) – 24 (92.3%). Among fractures of the neck, the type III occurred in 55.5% (10 out of 28 neck fractures), which twice exceeds the average data given in the literature [12].

Open fractures and rearfoot dislocations were diagnosed in 22 victims (24.7%). In patients with isolated lesions of one foot (10 cases) there were no open damages. These differences indicate more severe fractures in concomitant injuries. Bilateral open injuries were diagnosed in one victim.

Among the open rearfoot trauma, the type III prevailed – to 60% of all open fractures with the highest number of type IIIA injuries (36.4%).

Polysegmental fractures of the lower limbs were revealed in 34 victims (38.2%). Bilateral lower limb fractures were diagnosed in 7 affected (7.9%), unilateral – in 27 (30.3%).

We should note that combination of the femoral or tibial fracture and rearfoot fractures as well as ipsilateral rearfoot and ankle joint fractures occurred most frequently among polysegmental unilateral lower limb fractures. Intra-articular fractures of the ankle joint were found in 23 patients (25.8%) with rearfoot injuries, including Pilon fractures, diagnosed in 12 (13.5%), and malleolar fractures found in 11 patients (12.4%).

The most common combinations of bilateral and contralateral fractures were bilateral fractures and rearfoot dislocation, combination of uni- or bilateral injury of rearfoot and ankle joint fracture, and combination of uni- or bilateral rearfoot fractures and femoral fractures.

Open fractures and rearfoot dislocations were detected in 22 victims (24.7%). Patients with isolated injuries of one foot (10 patients) had no open defects.

The distribution of open rearfoot injuries in victims according to severity is presented in the Table 3.

Table 3

#### Distribution of open rearfoot injuries

Type of open lesions		Open fractures and dislocations			
		abs.		%	
Type I		2		9.1	
Type II		7		31.8	
Type III	Type III A	13	8	59.1	36.4
	Type III B		2		9.1
	Type III C		3		13.6
Total:		22		100	

In 11 patients out of 89, rearfoot fractures were not diagnosed upon admission to hospital because of the severity of accompanying injuries. The average time until fixation of fractures in these patients was 18 days. According to *Foot Function Index (FFI)*, the average score was 56.5.

Thus, patients with multisystem rearfoot injuries had the following features. Middle-aged men (mean 39 years) more often suffer such type of injury. The main mechanism of injury is falling from a height, the second is RTA. There is a large percentage (40%) of serious patients with damages of more than two anatomical areas of the body in the structure of multisystem trauma. The combination of rearfoot fractures with injury of the lower thoracic and lumbar spine and pelvis is of high incidence. For 38% of victims, polysegmental fractures of the lower limbs, often ipsilateral Pilon and malleolar damages are typical. Patients with concomitant injury tend to have multiple feet injuries (35%), particularly bilateral fractures of the calcaneus. Rearfoot fractures in patients with polytrauma are severe and open, about 60% are type III *Gustilo-Anderson* fractures.

## DISCUSSION

The problem of rearfoot damage in patients with polytrauma is socially significant. According to our information, people of more active groups normally suffer these injuries. Patients of young and middle age from 21 to 50 years accounted 84%. Most of the affected female were of child-bearing age. Our findings are consistent with the literature [1, 2, 6].

The late diagnosis is typical for rearfoot injuries. According to recent studies, up to 45% of injuries are diagnosed late or remain undiagnosed in the intensive care phase [4]. The main reason for this fact is that physicians focus on the most serious medical damage, threatening the life of a patient. Other reasons are shock, unconsciousness, alcohol and drug intoxication when it is not possible to establish contact with a patient [4, 5]. In addition, an important role is played by diminished clinical symptoms under the influence of severe underlying damage, especially in multiple lesions [5]. For example, in the case of severe damage in the thoracolumbar spine, the spinal pain softens foot fractures pain. Patients with a complicated spinal injury do not complain on the lower extremities.

Patients after falling from a height, as well as patients with multiple fractures of the lower limbs, pelvis, or after RTA are obligatory examined to exclude feet fractures. Therefore, repeated examinations over time are necessary, especially when patients regain consciousness.

We got poor functional outcomes in patients with missed rearfoot injuries (*FFI* 56.5) and late operations.

Alertness and active diagnostic measures can reduce the late detection of feet fractures and thus perform osteosynthesis in the early post-traumatic period when repositioning the bone fragments causes the least difficulties.

Features that affect treatment strategy, are determined with severe multiple injuries of both feet and other organs and systems, as well as concomitant fractures of the lower limbs. According to *Castel et al*, among patients with associated trauma there is a high percentage of multiple fractures of the lower limbs, combined with rearfoot fractures, up to 73% [9]. According to our study, these patients were up to 38%. Such a large number of patients with multiple trauma of the lower extremities represents another serious problem of feet trauma: the need to select the sequence of operations, elongation of the preoperative period due to the phasing of surgical treatment. And in cases of simultaneous Pilon and rearfoot damage there is a problem of surgical treatment. The presence of several surgical accesses in related regions of an ankle joint and foot increases the surgical injury, and consequently the risk of postoperative complications [10]. In our study, every fourth patient with a foot injury had lesions in the distal tibia.

Moreover, some studies concluded that rearfoot injuries as part of multisystem trauma are more severe than in an isolated injury, there is an increasing number of open and closed comminuted fractures, multiple feet injuries [2, 9]. Thus, the incidence of open "explosive" comminuted fractures of the calcaneus is 50% of all calcaneus fractures in patients with polytrauma [9]. The incidence of open fractures in an isolated foot injury is barely 8% [11]. Our study also showed a trend towards more complex rearfoot fractures in severe patients with multisystem trauma.

In such injuries, early fixation of fractures of the calcaneus and talus is essential. It is known that failures of conservative treatment for complex fractures of the calcaneus and talus reaches 80.5%. One of the key principles of modern treatment of seriously injured patients is early activation to restore all the damaged organs and systems [6, 7]. Until recently, the foot fractures had been considered less serious than diaphyseal fractures, and osteosynthesis could be maximally delayed or not performed at all. The study of long-term results showed that in patients with polytrauma and foot injuries, unsatisfactory results had been observed more frequently than in patients with isolated fractures [7]. This is associated with delayed active rehabilitation in these patients.

## CONCLUSION

Patients with multisystem rearfoot injuries are a particular group, where the tactics of diagnosis and treatment for isolated damage are not adequate. The general condition of these patients dictates the sequence and timing of surgical treatment of the foot. The high incidence of delayed diagnosis and the long time gap before the surgical treatment of the calcaneus and talus fractures lead to poor functional outcomes and reduced quality of life in these patients. A more complex nature of foot fractures requires qualitative preoperative planning and surgical risk assessment and, finally, the reasonable surgery.

## REFERENCES

1. Sokolov V.A. *Mnozhestvennye i sochetannye travmy* [Multiple and combined injuries]. Moscow: GEOTAR-Media Publ., 2006. 512 p. (In Russian).
2. Rammelt S., Biewener A., Grass R., Zwipp H. Verletzungen des Fusses beim polytraumatisierten Patienten. *Unfallchirurg*. 2005; 108 (10): 858–865.
3. Pfeifer R, Pape H.C. Missed injuries in trauma patients: a literature review. *Patient Saf Surg*. 2008; 2: 20.
4. Ahrberg A.B., Leimcke B., Tiemann A.H., et al. Missed foot fractures in polytrauma patients: a retrospective cohort study. *Patient Saf Surg*. 2014; 8 (1): 10.
5. Ardashev I.P., Ardasheva E.I., Afonin E.A., Voronkin R.G. Opyt lecheniya sochetannykh povrezhdeniy pozvonochnika i zadnego otdela stopy [Experience of treatment of combined injuries of the spine and rearfoot]. *Khirurgiya pozvonochnika*. 2009; 3: 14–19. (In Russian).
6. Tran T., Thordarson D. Functional outcome of multiply injured patients with associated foot injury. *Foot Ankle Int*. 2002; 23 (4): 340–343.
7. Stiegelmar R., McKee M.D., Waddel J.P., et al. Outcome of foot injuries in multiply injured patients. *Orthop Clin North Am*. 2001; 32 (1): 193–204.
8. Rammelt S., Dürr C., Schneiders W., Zwipp H. Minimal-invasive osteosynthese von kalkaneusfrakturen. *Oper Orthop Traumatol*. 2012; 24 (4–5): 383–395.
9. Castel E., Benazet J., Trabelsi R., et al. Fracture comminutive du calcaneum chez le polytraumatise. Analyse de 31 cas. *Rev Chir Orthop Reparatrice Appar Mot*. 2000; 86 (4): 381–389.
10. Dujardin F., Abdulmutalib H., Tobenas AC. Total fractures of the tibial pilon. *Orthop Traumatol Surg Res*. 2014; 100 Suppl 1: S65–S74.
11. Benirschke S.K., Kramer P.A. Wound healing complications in closed and open calcaneal fractures. *J Orthop Trauma*. 2004; 18 (1): 1–6.
12. Elgafy H., Ebraheim N.A., Tile M., et al. Fractures of the talus: experience of two level 1 trauma centers. *Foot Ankle Int*. 2000; 21 (1): 1023–1029.

Article received on 12 Feb, 2015

For correspondence:

**Vasily Bridzhevich Bondarev,**

Junior Researcher, the Department of Multiple and Multisystem Trauma

N.V. Sklifosovsky Research Institute for Emergency Medicine of the Moscow Healthcare Department

**E-MAIL: BONDAREV.NIISP@GMAIL.COM**