

# PUNCTURE CRYODESTRUCTION UNDER THE ULTRASOUND GUIDANCE FOR TREATMENT OF RELAPSING FACIAL BASALIOMAS

**A.M. Belyayev, G.G. Prokhorov, A.S. Madagov, M.I. Khadziyeva, Z.A. Radzhabova**

North-Western State Medical University named after I.I. Mechnikov, Saint Petersburg, Russian Federation

## ABSTRACT

Basal cell carcinoma is the most frequent human skin malignant tumor. The risk of recurrence exists regardless of the treatment method. The ultrasound assisted treatment in patients with face and neck skin basalioma is analyzed in this study. It was shown that the ultrasound assisted method with usage of modern domestic equipment allowed increasing the treatment efficacy of recurrent basal cell skin cancer.

**Keywords:** basal cell carcinoma of skin, ultrasonography, cryodestruction.

## INTRODUCTION

Basal cell skin cancer is one of the most common malignant skin neoplasms, and its management continues to be relevant.

Basaliomas occur in 45.0-96.8% of cases among malignant epidermal skin neoplasms [1-4]. The most common location is the face and hairy part of the head, which consequently requires some additional aesthetic treatment. A variety of treatment plans (surgical removal of the tumor, radiofrequency ablation, radiotherapy, laser and photodynamic therapy, cryosurgery, complex therapy) allows the the method of treatment to be individualized. It is known, that after the surgical treatment of skin cancer its recurrence rate is 12.5-34% [5, 6], and 1.2-48% after isolated laser destruction [7]. Radiation treatment has good results at the initial stages of the disease and does not differ in effectiveness from the other treatment for generalized lesions [8]. Cryodestruction may provide reliable tissue devitalization [9-11] when properly performed, but even after being performed by an experienced specialist the recurrence rate sill reaches 6% [12]. Thus, the risk of recurrence of the disease exists regardless of treatment methods, and in the future, patients with recurrent disease usually seek medical assistance in specialized institutions.

Recurrent infiltrative-ulcerous tumors of the face, complicated by infection and edema of soft tissues, often create difficulties at the stage of precision diagnosing. This happens due to topographic and anatomical changes in the area of recurrent tumorous growth associated with previously executed surgical procedures near vital organs, and local inflammation. It is extremely challenging to define borders of tumorous infiltration with physical diagnosis against the background of inflammatory edema, which complicates the choice of optimal treatment plan and adequate volume of intervention. At the same time, ultrasound examination of soft tissues has huge diagnostic capabilities and it is highly informative when monitoring cryosurgery [13].

Today, oncologists use new cryogenic equipment [13] and high-precision methods of non-invasive diagnosis. As shown in the study, its combination improves treatment outcomes.

**Aim of study.** To evaluate the results of treatment for basal cell skin cancer with modern methods of instrumental navigation and puncture cryodestruction monitoring when using minimally invasive cryogenic equipment.

## MATERIAL AND METHODS

Clinical studies have been conducted in the Department of Surgery for Head and Neck Tumors of N.N. Petrov Research Institution of Oncology.

The study involved 278 patients aged 36-89 y., having been observed over the last 5 years; 83.3% of patients were over 60 years, 64% were female. Lesions were located on the head and neck in 73.7% of all cases. As seen in Table 1, tumors most often affected the nose, skull cap and the medial angle of the eye.

*Table 1*

**Frequency of lesions of various anatomical regions**

No	Location of the tumor	Number of patients	Rate,%
1	Nasal region	94	29.3
2	Buccal region	26	8.1
3	Frontal region	24	7.5
4	Temporal region	16	5.0
5	Parietal region	12	3.7
6	Parotid-masseteric region	16	4.9
7	Nasolabial fold	16	4.9
8	Orbit	12	3.8
9	Occipital region	4	1.2
10	Mental region	4	1.2
11	Neck	12	3.7
12	Trunk and limbs	84	24.7
13	Total	320*	100

Notes: \* – some patients had several skin basaliomas

Of all patients with basal cell skin cancer of the facial region, recurrent tumors after previously conducted treatment were revealed in 81 patients (27% of cases). Of these, 34 recurrent basal cell carcinomas located in the nasal region, 5 – along the external angle of the eye, 7 – in the mental region, 4 – in the preauricular region, 13 – on the skin of the frontal region, 8 – in the buccal region, 6 – in the parietal-occipital region, 4 – in the temporal region. Basiliomas re-occurred from 5 months to 4 years after treatment. Among these patients, a large proportion of patients (42 cases) underwent laser therapy, 26 – surgical excision, and 13 – different variants of the combined treatment. Usually, recurrent tumors were multifocal, which borders were not clear, and in 32 patients, we revealed two points of recurrent growth in the area of postoperative scar. We considered the development of the tumor outside the scarring of the skin changes as cases of metachronous multicentric disease progression, which were not regarded as a local recurrence of the tumor.

The extension of the pathologic process was evaluated by the ultrasound scan preoperatively. We used ultrasonic devices of expert class, equipped with high-frequency sensors and Doppler scan. The study was conducted with an aid of the ultrasound scanner *HITACHI-HI VISION 900* using a linear sensor with a water cap and a built-in compression ultrasound elastography.

A water cap and a gel cushion in ulcer lesions helped determine the size of intradermal formations and assess the extent of infiltration in the subcutaneous fat.

The study was supplemented with Doppler mapping to visualize the surrounding blood vessels and more accurate determination of tumor growth borders.

Careful omnidirectional scanning provided a complete syntopic picture of the tumor growth area, vascular gates location, and invasive direction. It should be noted that the tumor growth in recurrent disease had not a concentric pattern. Invasions direction coincided with the lines of intermuscular crevices and cellular spaces, and extended to blood vessels. Infiltration of surface area, which was determined by palpation of a decaying infected tumor as an area of possible tumor invasion, could be clearly divided into sections of real tumor growth and inflammation area by ultrasound. At the same time, the lesion depth was often higher than the superficial extension which couldn't be determined physically. As a consequence, the final

conclusion about the prevalence of tumor invasion did not coincide with the initial clinical picture, and the affected area was actually deeper.

The most complex form of tumor infiltrates were found in the area of the orbit and the external auditory canal. Ultrasound scan results were crucial to determine the treatment method and scope of intervention exactly in these cases.

In cases of puncture cryodestruction, the procedure was planned basing on ultrasound scans in sequence. Initially, tumor borders were designated graphically and the size of the tumor was evaluated. Then, we found the optimal direction (directrix) for insertion of injection probes so as to primarily achieve deep lesions sections with minimum damage to major blood vessels and other important anatomic structures. After that, we compared the volume of individual parts of the tumor with specifications of the cryoprobe freezing capacity: cryo-chamber (active part) diameter and length, amount of possible cryoablation, shape of the resulting ice ball. Then, we put the scheme of suggested ice ellipses onto the "map" of the tumor. At the same time, we took into account the need to involve up to 5 mm of the healthy tissue around the tumor, as well as the need to form a single ice ball at isotherm "minus 40 °C" in each ellipse. Finally, we planned the number of cryoprobes, directrix, final location of instruments and target injection thermocouples. In some cases, while studying final surgery plans it became clear to add traditional applicators for superficial cryodestruction.

Surgeries were performed in an operating room under general anesthesia. The insertion of instruments under continuous ultrasound guidance included the access using a standard set of special accessories: stylet, introducer, trepanobiopsy needle, cryoprobe. The need for continuous monitoring of the ultrasound ablation process dictated a certain sequence of probes activation, set in the desired position. Priority of switching cooling mode in each area of the tumor depended on the instrument location: initially we shaped an ice sphere in the area of deep-seated cryoprobes, then in the area of superficially located probes. Such a sequence was explained by the fact that the ice ball with an edge clearly visible on ultrasound, was obscure for ultrasonic sounding, and formed a shadow covering deeper areas. After completion of puncture ablation, the superficial part of the tumor was managed by traditional applicators.

To perform puncture cryoablation, we used the modern cryotherapeutic system "MCS" (registration number 2014/2273 RZN) with a standard set of injecting cryoprobes of 1.5 mm, 3.0 mm and 5.0 mm and length up to 20 cm and a length of the cooled portion of 10 to 40 mm. This unit uses liquid nitrogen with pressure of up to 4 bar, and has the highest capacity among minimally invasive cryogene systems. In addition, the system provides the use of cryoprobes in the mode of active heating, allowing formation of protective thermal zones in deeper parts of the proximity of important anatomical structures.

For superficial cryoablation, we used cryogenic device AGKE-01 with a set of applicators (a diameter of 5-30 mm). The final operating temperature of surfaces of needles and applicators reached values ranging from minus 160 to minus 180°C. Cryoablation was carried out in three cycles of cooling with an exposure of 5 minutes in each of them. The time started after full coverage of a tumor with a single ice front. Temperature settings were kept within the prescribed limits automatically.

We report a clinical case.

A 62-year-old female patient with recurrent basal cell skin cancer of the ear and temporal region (after two successive surgical excisions of the tumor and subsequentl repeated surgery for recurrent disease).

Fig. 1 shows the lesion before treatment and 8 months after the discharge from hospital. Fig. 2 shows the results of the initial ultrasound, an explanatory diagram with borders for a scan, cryoprobes placement, shape and location of the planned ice front to perform cryoablation of the tumor.

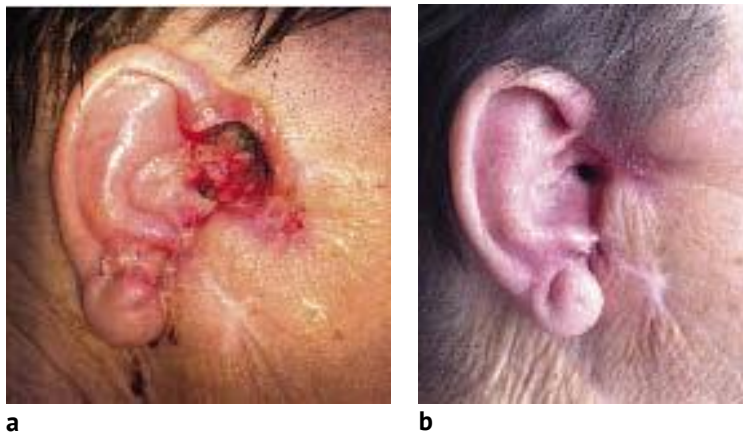


Fig. 1. Basal cell carcinoma before treatment and 8 months after thin needle puncture minimally invasive cryoablation with ultrasonic planning and guidance.

As shown on Fig. 2a, ultrasound scanning allowed clear visualization of the articular head of the mandible, articular capsule, tumor of a complex shape with invasion into deeper sections at a distance of 2 cm from the surface of the wound and partial involvement of the articular capsule and articular head of the mandible joint. Due to the complex contour of tumor infiltration (infiltration borders are marked on Fig. 2b), the calculated volume was impossible to determine exactly, and its value ranged from 5 to 6 ml. For complete coverage of all regions of the tumor it was necessary to use simultaneously more than two cryoprobes with needles of 1.5 mm in diameter and 15-mm-long cryochambers. The planned placement of instruments is shown on Fig. 2c. The projected volume of cryodestruction around the cryochamber of each cryoprobe was 4.5 ml according to specification, allowing the ice ellipses of each tool to overlap area of neighboring probes and form a single ice front according to preliminary calculations, most fully corresponding to the shape of the tumor (Fig. 2d). Partial destruction of the rear capsule and the temporomandibular joint, involved in the neoplastic process was regarded as inevitable. Lesions of the external ear backwards the acoustic meatus canal and at the basis of the earlobe, not shown in the scans, were easily managed with cryoablation applicators of AGKE-01 "Ingria" simultaneously.

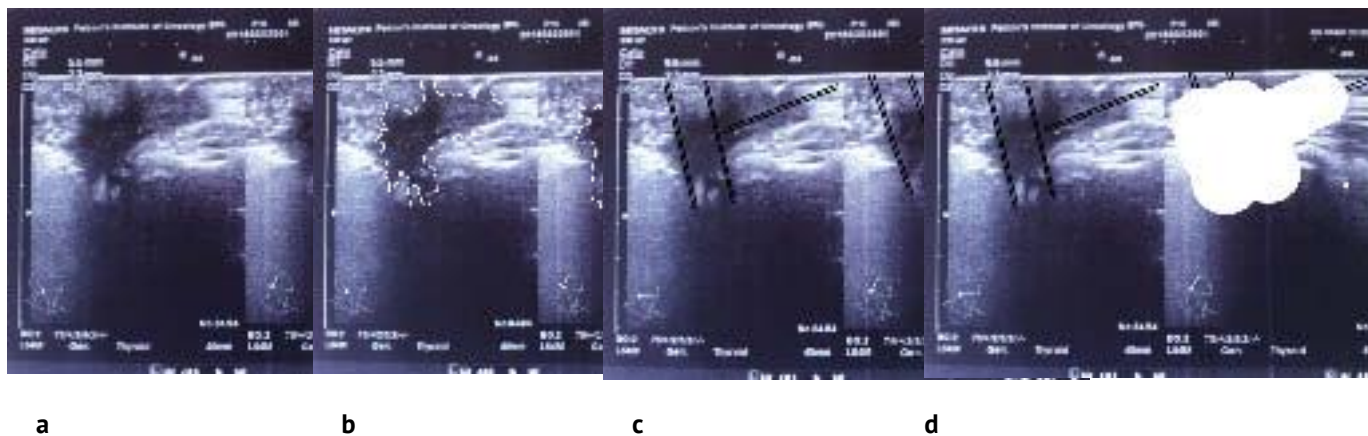


Fig. 2. Pre-operative ultrasound scans of the patient with recurrent basal cell carcinoma of the right ear and right temporal region, biplane (a), with designation of the tumor borders of the

tumor (*b*), planning pattern of cryoprobes position (*c*) and the projected area of deep puncture cryoablation (*d*). In the horizontal plane of the left side of each scan, the destruction area of articular head of mandible and capsule of temporomandibular joint are detected. Three cryoprobes were planned to be used with needles of 1.5 mm diameter. The predicted cryoablation area completely covers the contours of the tumor, leaving its superficial part intact.

Puncture cryodestruction lasted 1 hour and 20 minutes and was performed under general anesthesia in the operating room. The stage of cryoprobes introduction are shown on Fig. 3.

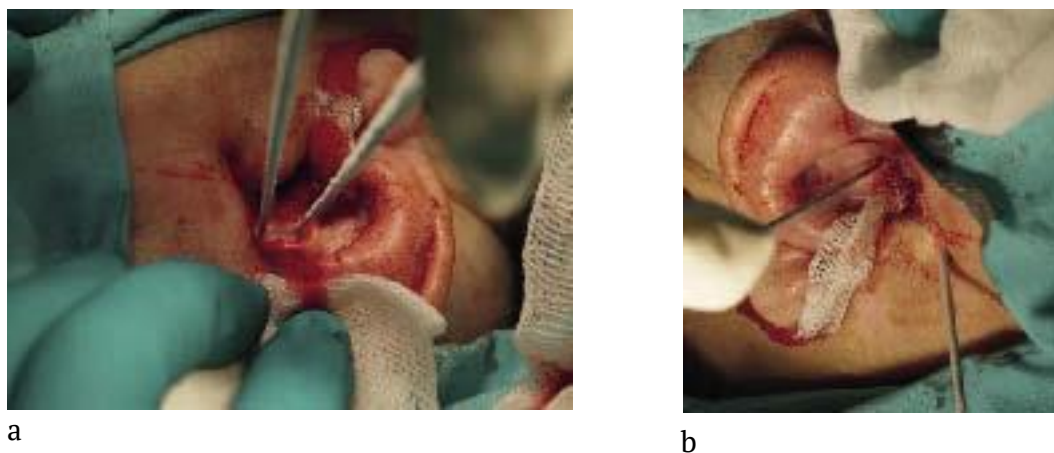


Fig. 3. Steps of puncture cryodestruction with cooling: *a* — deep parts and *b* — more superficial parts of the tumor

After the surgery, the patient complained of pain in the temporomandibular joint area while eating, limiting therefore the mobility of mandible. These symptoms persisted in the course of antibacterial therapy, as well as after the patient's discharge from the hospital and totally lasted up to 3 weeks. Liquorrhea from the surface of the wound was observed during the 1<sup>st</sup> week, then the necrotic crust formed, and the patient continued treatment on an outpatient basis, which included a daily dusting with "Baneotsin" powder and ordinary hygienic care of the operation area. Wound epithelialization was completed 3 months after cryoablation. The test general clinical and ultrasound examination 8 months later showed no evidence of disease recurrence, cosmetic results fully satisfied the patient.

## RESULTS

Patients easily underwent minimally invasive puncture cryoablation. Postoperatively, the general condition remained unchanged, as well as tissues surrounding cryoablation area. Within 2-3 days after the procedure significant edema of facial soft tissues naturally developed, in areas of applicative cryodestruction lymphorrhea was observed. At the same time, the wound care within the 1<sup>st</sup> week consisted of skin antiseptics and timely change of dressings in the course of antibiotics. After formation of dry necrotic crust in the area of cryonecrosis, the operation area did not require medical supervision; demarcation, crust rejection and subsequent epithelialization of the wound flowed naturally.

Complications during and after cryoablation were not observed. Antibiotic therapy prevented infectious complications and made necrectomy or secondary debridement unnecessary. After puncture cryoablation of deep tumors through unaltered skin, the puncture site did not require additional care and recovered without the formation of scars.



With the correct formulation of indications for surgery, there were no absolute contraindications to treatment for basalomas with cryodestruction. Associated chronic diseases and old age of patients were not contraindications to the treatment. Moreover, physicians were rather inclined to perform this minimally invasive procedure.

With an overall positive result, a number of issues remain the subject of ongoing research. Among them — the adequacy of cryogenic technologies in cases when bones and articular surfaces are involved into neoplastic process, the possibility of spread to important anatomical structures in topographically more complex cases: large blood vessels, pneumatic cavities, hollow organs.

The effectiveness of treatment in patients with recurrent forms of basal cell carcinoma, and the immediate results were evaluated 6-8 months after the procedure on the basis of clinical examination, repeated morphological study, the absence of recurrence and changes that caused functional or cosmetic defect.

In general, patients with recurrent forms of the disease had complete regression of tumors in 93% of cases. Among patients of this group, who were treated by puncture cryoablation with preoperative ultrasonography and intraoperative monitoring, there were no recurrent cases within 8 months.

Thus, on the basis of clinical and pathologic evaluation of the immediate and early results of treatment for basal cell skin cancer in its recurrent forms, it can be stated that the ultrasonic diagnosis and monitoring methods in combination with modern thin cryodestruction expand treatment options for patients with recurrent basal cell skin cancer of head and neck with a complex anatomical location of the tumor. Puncture minimally invasive cryotherapy, featuring high efficiency, allows to destroy the tumor completely, is easily tolerated by patients and provides an optimal cosmetic effect.

## CONCLUSIONS

1. Ultrasound omnidirectional scanning of recurrent forms of basal cell skin cancer gives a complete picture of the tumor growth topography, and allows to monitor the process of precision cryoablation in real time.

2. Puncture minimally invasive cryoablation with the use of modern equipment is the best way to treat recurrent tumors of difficult anatomical areas.

3. In cases of a recurrent disease, the ultrasonic method and new domestic equipment improve the effectiveness of treatment.

## REFERENCES

1. Blokhin N.N., Trapeznikov N.N., Aliev D.A. *Plasticheskie operatsii pri zlokachestvennykh opukholyakh kozhi* [Plastic surgery for malignant skin tumors]. Moscow: Meditsina Publ., 1979. 200–204. (In Russian).
2. Kubanova A.A., Martynov A.A. Mesto zlokachestvennykh novoobrazovaniy kozhi v strukture onkologicheskoy zaboлеваemosti naseleniya Rossiyskoy Federatsii [Place of malignant tumors of the skin cancer incidence in the structure of the population of the Russian Federation]. *Vestnik dermatologii i venerologii*. 2007; 6: 19–24. (In Russian).
3. Staples M.P., Elwood M., Burton R.C. Non-melanoma skin cancer in Australia: the 2002 national survey and trends since 1985. *Med J Australia*. 2006; 184 (1): 6–10.
4. Tozaki M., Fukuma E. Ultrasound-and MRI-guided cryoablation for small breast cancer. In: K. Xu, N. N Korpan, L. Niu, eds. *Modern cryosurgery for cancer*. Vienna, 2012. 511–523.
5. Katunina O.P., Pryadkina E.V. Ul'trazvukovoe skanirovanie kak neinvazivnyy metod diagnostiki bazal'no-kletochnogo raka kozhi [Ultrasound scanning is non-invasive diagnosis of basal cell skin cancer]. *Vestnik dermatologii i venerologii*. 2009; 5: 63–67. (In Russian).
6. Frantsiyants E.M., Pozdnyakova V.V., Irkhina A.N. Lechenie bol'nykh mestno-rasprostranennym i retsidivnym ploskokletochnym rakom kozhi [Treatment of patients with locally advanced and relapsing squamous cell carcinoma of the skin]. *Sibirskoe meditsinskoe obozrenie*. 2010. 63 (3): 88–91. (In Russian).
8. Hulyalkar R., Rakkhit T., Garcia-Zuazaga J. The role of radiation therapy in the management of skin cancers. *Dermatol Clin*. 2011; 29 (2): 287–296.
9. Korolev Yu.V. Kriokhirurgicheskoe lechenie radiorezistentnykh retsidivnykh form bazal'nokletochnogo raka kozhi [Cryosurgical treatment radioresistant relapsing forms of basal cell skin cancer]. *Meditsinskiy al'manakh*. 2010; 2 (11): 294–296. (In Russian).
10. Pustynskiy I.N., Paches A.I., Tkachev S.I., et al. Krioluchevoe lechenie bol'nykh mestnorasprostranennym rakom kozhi shcheki [Cryo-radiation treatment of patients with locally advanced skin cancer of the cheek]. *Sibirskiy onkologicheskii zhurnal*. 2013; 6: 5–8. (In Russian).
11. Davydov M.I., Aksef' E.M. Statistika zlokachestvennykh novoobrazovaniy v Rossii i stranakh SNG v 2009 g [Statistics of malignant tumors in Russia and the CIS countries in 2009]. *Vestnik RONTs im NN Blokhina RAMN*. 2011; 22 (3) Suppl 1: 4–170. (In Russian).
12. Popovich V.I. *Sovremennyye metody lecheniya bol'nykh rakom orofaringeal'noy oblasti, kozhi i nizhney guby: avtoref. dis. ... d-ra med. nauk* [Modern methods of treatment of patients with oropharyngeal cancer, skin and lower lip: Cand. med. sci. diss. synopsis]. Moscow, 2000. 48 p. (In Russian).
13. Belyaev A.M., Prokhorov G.G. Kriogenyye tekhnologii v onkologii [Cryogenic technologies in Oncology]. *Voprosy onkologii*. 2015; 61 (3): 317–322. (In Russian).

ARTICLE RECEIVED ON 23 NOV, 2015

FOR CORRESPONDENCE:

ADAM SULEYMANOVICH MADAGOV

POST-GRADUATE STUDENT OF THE DEPARTMENT OF ONCOLOGY,

NORTH-WESTERN STATE MEDICAL UNIVERSITY NAMED AFTER I.I. MECHNIKOV, SAINT  
PETERSBURG, RUSSIAN FEDERATION

E-MAIL ADDRESS: [MADAGOV.A@MAIL.RU](mailto:MADAGOV.A@MAIL.RU)